

# IMAGING

## Management

RADIOLOGY, CARDIOLOGY, INTERNAL MEDICINE, SURGERY, MANAGEMENT, IT, EUROPE, ECONOMICS, TRENDS, TECHNOLOGY

Magnetic Resonance Systems

DICOM compliant systems

Medical Intervention

Nuclear Technology

PACS Technology

Tele-radiology

Tele-medicine

Radiography

Oncology

Urology

X-Ray

Radiology

Neurology

Ultrasound

CT Scanning

Management

PET/CT Technology

R&D and research units

Integrated Data systems

Film and Screening Systems

**NUCLEAR MEDICINE –  
A European Perspective**

**PET PRODUCT COMPARISON TABLES**

**COUNTRY FOCUS – BELGIUM**

ISSN = 1377-7629

VOLUME 5 • ISSUE 1/2005 • MARCH - APRIL

## HISTOSCANNING™: A NEW ULTRASOUND-BASED TECHNOLOGY FOR THE NON-INVASIVE DETECTION OF CANCERS IN SOLID ORGANS

The current status and reliability of imaging-based diagnosis is principally dependent on the interpretative ability of an individual practitioner who has to decide whether an abnormal image he sees is due to normal tissue proliferation, a benign neoplasm or a malignant process. With specific reference to ultrasound imaging; due to the human eye's inability to process large quantities of grey level information, this

raw data (RF signals) acquired by real 3D ultrasound machines. Since the majority of today's ultrasound modalities restrict wide access to grey level voxel data (raw data that was processed by the ultrasound built-in operating procedures for the production of grey level video images), HistoScanning also supports utilization of data of this nature in client server applications.

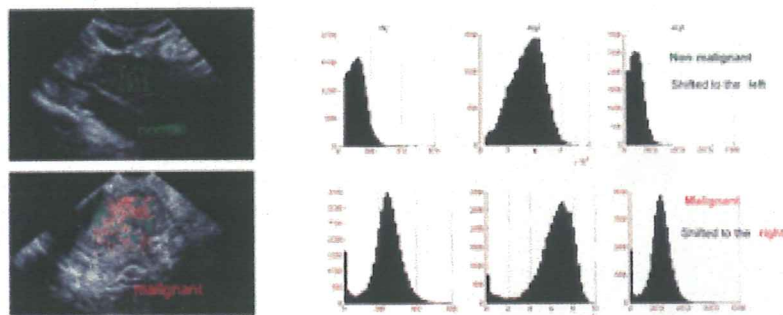


Figure 1: • each algorithm computes a certain feature of the immediate surrounding tissue (20x20 window) with the selected ROI • the results are collected in histogram plots (number of scores which have a certain value) and finally translated on a scale range.

technology is currently not used for cancer screening, where the identification of small amounts of malignant tissue embedded in normal tissues having a regular anatomical appearance is a basic requirement.

Advanced Medical Diagnostic is in the process of introducing HistoScanning, an innovative software technology complementary to ultrasound systems. HistoScanning is designed to enhance the non-invasive, ultrasound-based detection of cancers in solid organs, by performing accurate characterization of local tissue morphology.

HistoScanning technology is conventionally implemented as a client server application that permits tele-medicine analysis services to enhance the ultrasound-based diagnosis of pelvic masses presenting as suspected ovarian cancer.

In its preferred configuration, HistoScanning analysis should be applied to backscattered

HistoScanning is not only a tool which facilitates the interpretation of static or dynamic video images. By extracting and quantifying statistical features from backscattered ultrasound waves, HistoScanning makes possible the characterization of tissue morphology which typifies the cancer process.

### How does HistoScanning work?

The processing core of HistoScanning consists of 'characterization algorithms' that extract data from the backscattered ultrasound waves in the form of arithmetic data corresponding to cancerous transformations of the tissue under examination (i.e., disorganisation, invasion, abnormal nuclei).

To illustrate, Figure 1 shows typical results taken from the analysis of two ovaries (one normal, one cancerous) by three characterization algorithms that form the processing core of Ovarian HistoScanning. The histograms

DROR NIR, PhD  
 ADVANCED MEDICAL DIAGNOSTICS  
 555 ENGELAND STREET, (1180) BRUSSELS  
 TEL: +32-2-600 50 10  
 DRORNIR@HISTOSCANNING.COM

ANDRÉ-ROBERT GRIEVEGNEE, MD  
 PHILIPPE AUTIER, MD  
 2 UNITS OF EPIDEMIOLOGY AND PREVENTION  
 JULES BORDET INSTITUTE, BRUSSELS

reveal pixel data represented numerically (Y axis) matching a numerical pattern (X axis) specifically detected by each algorithm. One can observe that, in the presence of cancer, the numerical values attached to pixel data shift markedly to the right, i.e., to a higher numerical value. The two pictures represent the way in which HistoScanning results are displayed on a video screen with ultrasound image capability. Each spot corresponds to a 20 by 20 pixel of data. A green spot corresponds to HistoScanning values indicative of normal tissue, and a red spot corresponds to HistoScanning values indicative of cancerous process. The full analysis of the 3D data volume is achieved through the successive analysis of 2D frames.

Part of any HistoScanning application consists of steering algorithms which permit the accurate spatial positioning of the local, analysed data as a component of the 3D representation of the complete organ. Accordingly, HistoScanning will analyze that volume of data which corresponds to specific regions of a solid organ as determined by the echographer (the so-called Region of Interest - ROI), and then locate the probable outcome of the cancerous process within the 3D representation of the organ. In this respect, HistoScanning is likely to improve the interest of oncologists in 3D ultrasonography.

### Ovarian cancer

Ovarian cancer is characterized by late detection at an advanced stage resulting in poor survival rates. As a result, it is the most frequent cause of death from gynecological cancer and represents a fifth of all cancers. Every year, within the European Union (15 member states), almost 33,000 women are diagnosed with ovarian cancer, whilst 24,000 die from the disease. Because of the location of the ovaries, most ovarian cancers show few early-stage symptoms. As a consequence, more than two thirds of ovarian cancers are detected at a late stage, when the probability of surgical cure is minimal. Improvements in the early-detection rates for breast cancer, cervi-

cal cancer and endometrial cancer have made substantial inroads into mortality figures but there is no corresponding improvement in ovarian cancers. Because of the difficulties in diagnosing ovarian cancer, many women undergo surgical or endoscopic exploration of the pelvis coupled with removal of ovaries because of an abnormal image at ultrasound. In many of these cases no cancer is detected during biopsy. In consequence, more than 90% of women undergoing surgery following an abnormal pelvic examination turn out not to have cancer.

### Ovarian HistoScanning

The processing core of ovarian HistoScanning was developed with the aid of animal experiments in nude mice implanted with human ovarian cancer (Figure 2). During a preliminary clinical study that took place in Israel in 2002 and 2003, the three characterization algorithms of ovarian HistoScanning were calibrated for human subjects with the pre-condition that no cancer could be missed. HistoScanning analysis of 3D ultrasound files was compared with results taken from patient histology. HistoScanning correctly identified all ovarian cancers diagnosed in these women, and labelled 32% ovaries, previously considered normal or with benign tumour, as suspicious (results in publication). The conclusion of that preliminary study was that HistoScanning has the potential to detect ovarian cancers with very high sensitivity.

Current research is directed towards the reduction of false positive rates. A European multicenter study began in 2004 in eight medical centres, with the objective of testing the validity of Ovarian HistoScanning in the detection of ovarian cancer.

US-image and serum tumour markers based on the diagnosis of pelvic masses suffer from consistently high false negative rates of between 30 and 15%. This figure appears very difficult to reduce. Consequently, in most cases of abnormal findings in post-menopausal women, laparoscopic surgery is performed systematically for diagnostic pur-

poses. However, cancer is found in only 1 to 5% of patients following surgical investigation. (Sadik et al., 1999).

In pre-menopausal women, ovarian cancers are rare (less than 5% of ovarian masses), while cysts are frequent, and a watchful waiting attitude, or laparoscopic investigation are frequently adopted instead of surgical intervention.

Using HistoScanning analysis to supplement ultrasound examination could help corroborate the absence of malignant ovarian tissue

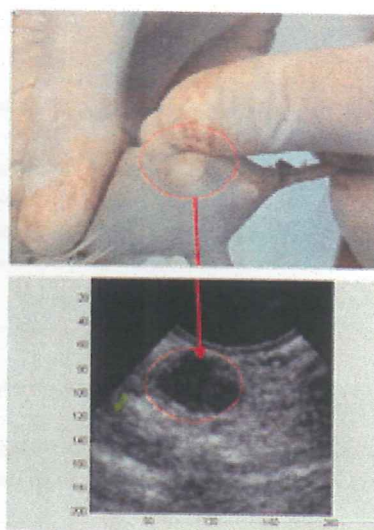


Figure 2: Selection of characterization algorithms using nude mice implanted with human ovarian cancer

arising from suspicious ultrasound findings. Thus, HistoScanning has the potential to strengthen confidence in the watchful waiting treatment modality and helps reduce the need for laparoscopy when the presence of cancer is considered possible.

### The perspective of ovarian cancer screening

Screening for ovarian cancer is often advocated, in order to increase detection rates of ovarian cancer at an early stage, when the

cancer is still considered surgically curable. But current screening methods based on echographic examination using standardized morphological criteria and measurement of serum CA 125 antigen do not appear optimal, as a combination of these two techniques still yields false negative rates of 10-15%; rates that seems difficult to reduce. (Kurtz et al., 1999; Grab et al., 2000; Huber et al., 2002; Osmer et al., 1996; Shutter et al., 1994). A new approach to ovarian cancer screening would consist of ultrasound machines equipped with Ovarian HistoScanning specifically designed to assess large numbers of women. R&D and clinical studies into ovarian cancer screening will start when the detection of ovarian cancer has reached a high level of specificity.

#### Other potential applications of HistoScanning

Medical and technical researchers have begun to adapt HistoScanning for tissue characterization and early cancer detection in other organs, principally the prostate. HistoScanning has the potential to serve as a guidance tool in minimally invasive diagnostic procedures, such as biopsies (e.g. of the prostate or the breast), or for use in minimally invasive treatment modalities (e.g. for the prostate). It is also anticipated that HistoScanning will be able to detect cancerous processes in the thyroid, the uterus and the liver. For each application, different characterization algorithms will be developed.

#### Cancer, HistoScanning and three-dimensional echographic examination

In conventional 2D scanning the operator moves a transducer across an organ, whilst assessing separate video images (each representing a single 'slice' of tissue) and, simultaneously attempting to detect any deviations from what his memory and experience tell him is the 'healthy' image. Current virtual 3D technology uses special transducers that automatically sample a whole area of tissue into many slices taken at regular intervals. These machines output a 3D image

that can be further manipulated by the echographer. In oncology, during organ exploration or biopsy, recently introduced three-dimensional (3D) ultrasound technology is not considered as offering a clear-cut advantage over familiar, inexpensive 2D echography. This is mainly due to the inability of the eye to process, in real time, a large quantity of information. In consequence, despite of the advance of being able to acquire accurately 3D information about the whole organ, 3D ultrasound techniques have not been considered as a new 'standard' in imaging-based diagnosis, other than in the field of obstetrics. HistoScanning will change all this, and permit the introduction of advanced ultrasound technologies into diag-

nostic domains currently dominated by riskier and more expensive MRI and CT scanning systems.

3D imaging supplemented by HistoScanning offers the operator the advantage of automatic 'flagging' of regions of interest (ROIs) within an organ. No longer will practitioners be looking for a 'needle in a haystack'. HistoScanning has even greater advantages for 3D ultrasound users, as it reports results in a form that pinpoints the exact location of characterized 'lesions of interest' within the 3D environment. This latter property permits the prioritizing of lesions in real time, and will facilitate the future use of 3D ultrasound systems as accurate, stereotatic biopsy and therapy tools.

#### FOOTNOTES

\* HistoScanning is a registered trademark, US Patent No. 6,785,570, and International Application No. PCT/IL02/00481 (Ref: 139577-1).

\* More technical information is available at the url: [www.histoscanning.com](http://www.histoscanning.com)

\* Institut Jules Bordet Institute, Brussels - Belgium, Hôpital Saint Pierre Hospital, Brussels - Belgium, Istituto Europeo di Oncologia, Milano - Italy, Universitätsklinikum Tübingen - Germany, Groupe Hospitalier Pitié-Salpêtrière, Paris - France, Karolinska Hospital, Stockholm - Sweden, Rabin medical center - Israel, Centre Jean Perrin, Clermont-Ferrand - France.

#### REFERENCES

- ACOG committee opinion (2003) The role of the generalist obstetrician-gynaecologist in the early detection of ovarian cancer. *Int J Gynecol Obstetrics* 80: 235-238.
- Grab D, Flock F, Stohr I, Nussle K, Rieber A, Fenschel S, Brambs HL, Reske SN, Kreienberg R (2000) Classification of asymptomatic adnexal masses by ultrasound, magnetic resonance imaging, and positron emission tomography. *Gynecol Oncol* 77: 454-9.
- Heitz APM, Odicino F, Maisonneuve P, Bellier JL, Benoit JL, Crosman WT, Ngan HYS, Sideri M, Pecorelli S (2000) Carcinoma of the ovary. *J Epidemiol Biostat* 6: 107-108.
- Huber S, Medl M, Baumann L, Czemberek H (2002) Value of ultrasound and magnetic resonance imaging in the preoperative evaluation of suspected ovarian masses. *Anticancer Res* 22: 2501-7.
- Kurtz AB, Tsirikas JV, Tempary CM, Hamper UM, Arger PH, Bree RL, et al (1999) Diagnosis and staging of ovarian cancer: comparative values of Doppler and conventional US, CT, and MR imaging correlated with surgery and histopathologic analysis—report of the Radiology Diagnostic Oncology Group. *Radiology* 212:19-27.
- Osmer RG, Osmer M, von Maydell B, Wagner B, Kuhn W (1996) Preoperative evaluation of ovarian tumors in the premenopause by transvaginosonography. *Am J Obstet Gynecol* 175: 428-34.
- Sadik S, Onoglu AS, Gokdeniz B, Tuzan E, Taskin O, Wheeler JM (1999) Laparoscopic management of selected adnexal masses. *J Am Assoc Gynecol Laparosc* 6: 313-6.
- Schutter EM, Kenemans P, Sohn C, Kristen P, Crombach G, Westermann R, et al (1994) Diagnostic value of pelvic examination, ultrasound, and serum CA 125 in postmenopausal women with a pelvic mass. An international multicenter study. *Cancer* 74:1398-406.